

**Name...,  
Xyo SF M, SJ  
Date**



# I- Complain - History

✦ Problem: **Date**  
-LH lameness

✦ Anamnesis:  
-End 2004:  
  
-Then...

✦ Physical activity:  
-Rest

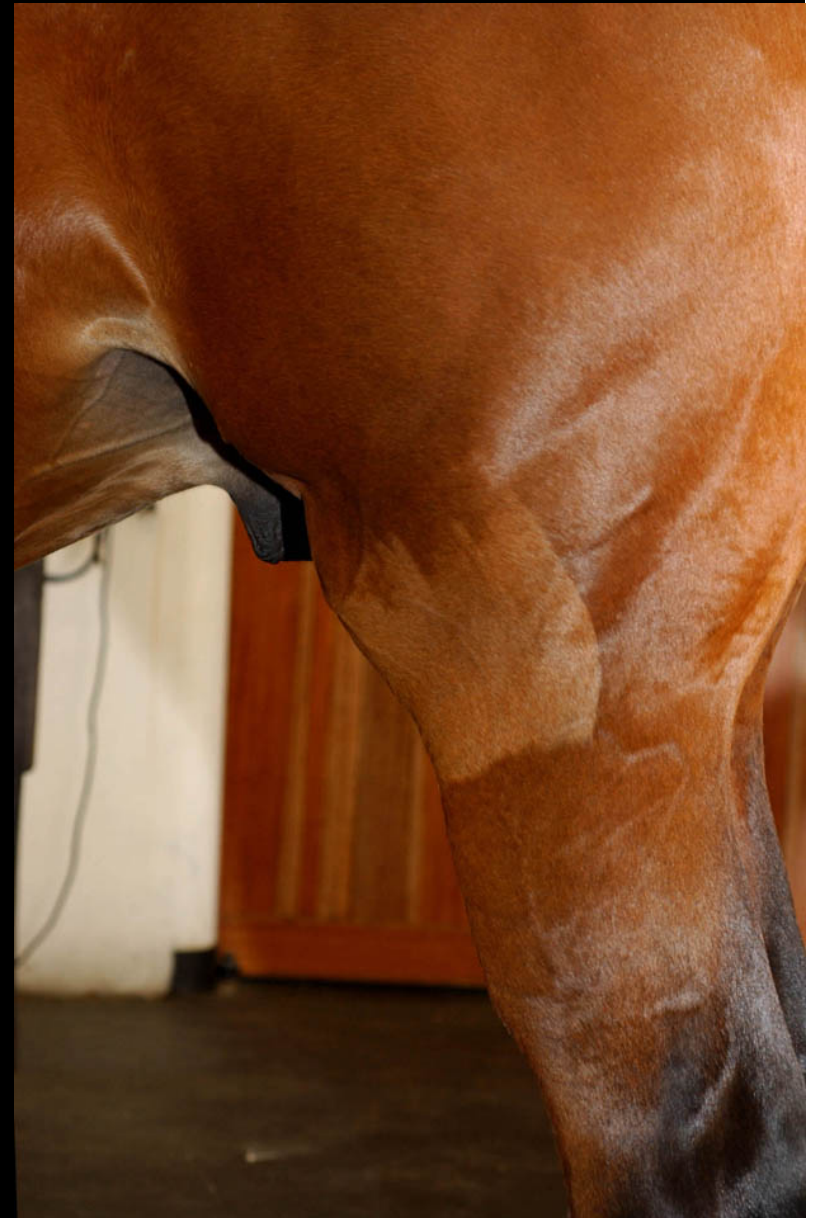
## II- Clinical examination

✦ Physical examination:

✦ Distension

- Left gluteal muscle atrophy

-



✦ Dynamic examination:

➔ VIDEO



# ✦ Dynamic examination: **SYNTHESIS**

## □ Walk

- Reduced ...

## □ Trot

- LH lameness (grade 2/5) at the trot  
in straight line, on hard ground
- Worsening on the corresponding circle (3/5):  
left circle - limb inside
- Positive LH FT (L° 3/5)

## □ Canter

- Reduced ...

### III- Diagnostic approach:

- Diagnostic analgesia ?
- Radiography ?
- Ultrasonography ?
- Other ?

➔ Imaging of XXX based on  
physical examination and ...!

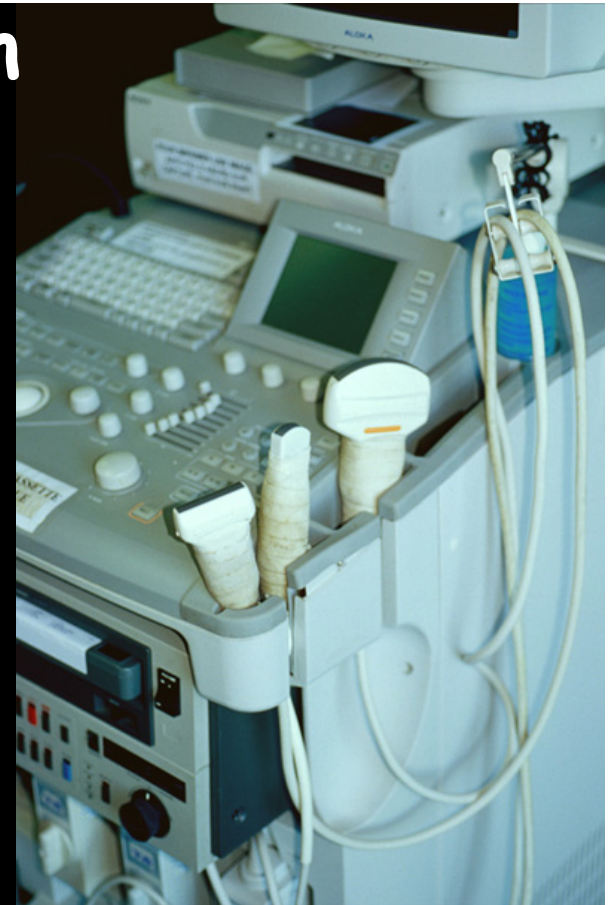✦ Radiographic examination: **Date**

## 👉 conclusion

- soft tissue ...
- bone ...



# ✦ Ultrasonographic examination



## 👉 conclusion

- soft tissue ...
- bone ...

# IV- Conclusions / Management

## ✦ Diagnosis

1- Lesion of the

2-

## ✦ Management

### □ Corrective shoeing:

1- Shoe with reduction of

### □ Physical activity:

1- Rest during ... with ...

# ✦ Treatment

## □ Local treatment

- 1- USG injection of ...
- 2- ???

## □ Systemic treatment

- 1- X
- 2- Y

## □ Surgical treatment

- 1- X
- 2- Y

## □ Any other ideas ...

- ...

## ✦ Prognosis

1- Fair for ...

-Reason:

2- Reasonably good for ...

## ✦ Follow up - Outcome

- Re-examined on ...
- lame again in...

# V- Discussion

## A- Diagnosis/documentation

1- Key-aspects ...

2- Interest of ...



# V- Discussion

## B- Epidemiology

1- Rare lesion

2- Other cases

# V- Discussion

## C- Etiopathogenesis

- WB X rotation

- Flexion ??

- ...

# V- Discussion

## D- Prognosis

- Key criteria:

1-

2- Management...

# V- Discussion

*E- Any other data ...*